MAGNETIC RESONANCE IMAGING OF CHEST WALL LESIONS

James D. Collins, MD, Marla Shaver, MD, Poonam Batra, MD, Kathleen Brown, MD, and Anthony C. Disher, MD
Los Angeles, California

Magnetic resonance imaging (MRI) demonstrates surface anatomy, nerves, and soft tissue pathology. Selective placement of the cursor lines in MRI displays specific anatomy. The MR images can then be used as an adjunct in teaching surface anatomy to medical students and to other health professionals. Because the normal surface anatomy could be imaged at UCLA's radiology department, it was decided to image soft tissue abnormalities with MR to assist in patient care.

Patients imaged were scheduled for special procedures of the chest or staging lymphangiograms. Patients were placed into categories depending on known diagnosis or interesting clinical presentation. The diagnostic categories included Hodgkin's disease, melanoma, carcinomas (eg, lung or breast), lymphedema, sarcomas, dermatological disorders, and neurological disorders. All images were orchestrated by the radiologist. This article discusses both the teaching and clinical impact on patient care. (*J Natl Med Assoc.* 1991;83:352-360.)

Key words • MRI chest wall • MRI anatomy • MRI lymphedema • MRI lymphangiography • MRI brachial plexus • MRI melanoma

From the Department of Radiological Sciences, UCLA School of Medicine, Los Angeles, California. Presented at the National Medical Association's 94th Annual Meeting in Orlando, Florida, July 17, 1989. Requests for reprints should be addressed to Dr James D. Collins, Department of Radiological Sciences, UCLA Center for the Health Sciences, Los Angeles, CA 90024.

Clinical observations bring questions of whether models of radiological pathological correlation can be constructed to test the observations.[1-4] A thesis or theory is challenged by deriving a protocol. The radiologist who takes the opportunity to observe the clinical and pathological environment of the academic arena will enhance teaching and research within the clinical setting. Observations may come from reading an endless number of radiographs or surgical operative reports, or from performing special procedures.[3,5,6]

A series of tests may be designed for animal research,[3,7] or data may be stored based on patient observation. The information is recorded, and statistics are reviewed to evaluate the theory. If the theory is valid and can be modified for patient care, the procedure may be adopted.[7-9]

Magnetic resonance imaging (MRI) demonstrates surface anatomy, nerves, and soft tissue pathology.[10-13] Selective placement of cursor lines in MRI displays contiguous anatomy. Therefore, the images can be used as an adjunct in teaching surface anatomy to medical students and to other health professionals.

The radiologist consults on procedures for patient care and then performs a variety of special procedures. Because the clinician relies on the competency of the radiologist, it seems logical to offer MRI as a tool in the staging of disease. Rounds with the medical, surgical, and oncology services allow excellent opportunities to increase rapport with faculty, house staff, and medical students. The radiology department at UCLA School of Medicine strongly encourages the above approach.

Some of the patients at UCLA had known diagnoses, including Hodgkin's disease, melanoma, metastatic

TABLE. SUMMARY OF 115 PATIENTS PRESENTING WITH CHEST WALL DISEASE DISPLAYED BY MR (1986-1989)

Clinical Problem	Pain	Edema	Malignant Tumor	Benign	Autoimmune Disease	Infectious Disease	Total
Breast carcinoma	X	X	18	14	—	—	32
Idiopathic		X	—	—	—	—	15
Infectious	X	X	—	—	—	1	1
Keloids			—	3	—	—	3
Lung Ca metastasis	X	X	4	—	—	—	4
Lymphedema	X	X	9	—	—	1	10
Lymphoma	X	X	16	—	—	—	16
Melanoma*			27	1	—	—	28
Neuropathy	X		—	—	1	1	2
Normal anatomy		X	—	—	1	—	1
Sarcoma	X	X	2	—	—	1	3
						Totals	**115**

***One patient (history of melanoma of the retina) had a rib fracture simulating a chest wall mass; no tumor present on biopsy; patient alive and free of tumor.**

carcinomas (eg, lung or breast), lymphedema, dermatological disorders, and neurological disorders (Table). Several patients presented with pain, swelling, or lymphedema of the chest wall. The MRI findings were reviewed and shared with the various specialties and subspecialties.

This article demonstrates soft tissue pathology of the chest wall as displayed by MR. The contiguous anatomy, teaching, and clinical impacts of MRI on patient care are discussed.

METHODS AND MATERIALS

Patients were imaged when the clinician had a question of chest wall involvement after reviewing plain chest radiographs or after other radiological examinations. The radiologist reviewed the patient's clinical history and radiographs, and interviewed the patient before the MRI examination.

All images were recorded with a spin echo of TE = 28 and TR = 500 using a 0.3 Tesla Fonar permanent magnet. Axial, coronal, sagittal, and oblique planes were chosen to image the anatomy for comprehensive learning. Anatomical landmarks were maintained for orientation and display. Enlarged serial images were selected for visual association. Images were interleaved to increase definition. Negative and positive mode images were obtained to enhance fascial planes and the gross pathology.[4,10]

RESULTS

One hundred fifteen patients with suspected chest wall pathology were imaged between 1986 and 1989. Patients were subdivided into categories based on their presenting clinical diagnosis. The Table outlines the results. Magnetic resonance demonstrated detectable abnormalities in 97 patients. Biopsies were obtained and correlated with the MRI examinations.

The Table lists the patients according to their known presenting clinical problem. The idiopathic category was assigned to patients who presented with a primary complaint of pain (point tenderness) or swelling. A "bump" on the skin was the most common secondary complaint. The remaining columns represent the biopsy-proven secondary diagnosis obtained after MRI examination.

DISCUSSION

Since 1967, the review of surgical operative reports has allowed the UCLA radiology department to be aware of the operations routinely performed within the hospital. The surgical operative reports and pathology reports have become a major contribution to teaching and research within our department by opening new avenues for the radiologist to suggest MRI examinations. After presenting MRI exhibits on chest and shoulder anatomy to the oncology services, cases were referred. We have continued to present our findings to subspecialties, increasing the requests for chest MRI examinations.

The television monitor coupled to the radiograph fluoroscopic screen increased the radiologist's ability to place catheters and needles. Computerized axial tomography introduced cross-sectional images. Magnetic resonance imaging provides a challenge to the radiolo-

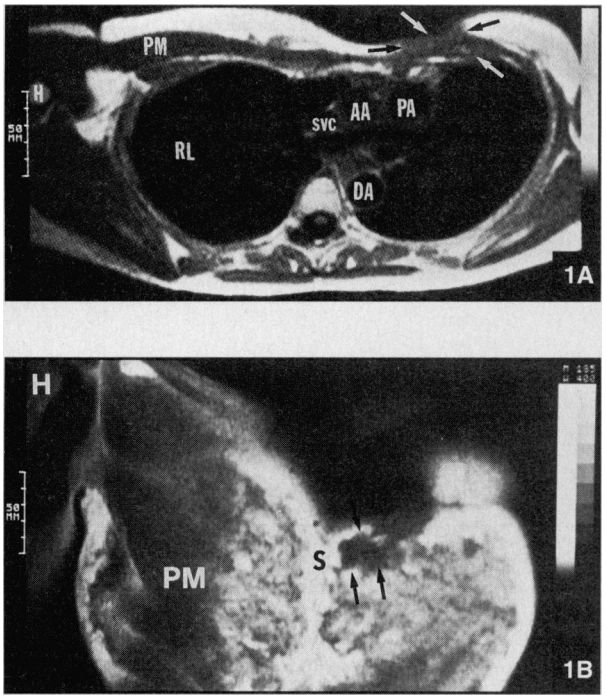

Figures 1A-B. Axial (transverse) and coronal images of metastatic breast tumor infiltrating the chest wall (arrows). (S = sternum, PM = pectoralis major muscle, RL = right lung, H = humerus, AA = ascending aorta, DA = descending aorta, SVC = superior vena cava, and PA = pulmonary artery.)

gist to display gross pathology that requires relearning anatomy.[14]

Breast Carcinoma

In the breast carcinoma category, the clinicians wanted to know if metastatic disease was present. These patients presented with complaints of pain or swelling. Some of them presented with "bumps" on the skin that were thought to be metastatic disease. Thirty-two patients were studied. Eight of these patients had recurrent tumors as demonstrated by MRI and confirmed by biopsy. One of the eight patients, a 39-year-old woman who presented with pain and tenderness over the resected left breast, illustrated the value of contiguous surface anatomy imaging with MRI. The MRI confirmed a chest-wall mass contiguous with the left internal mammary lymphatics, invading the soft tissues and adjacent bone (Figures 1A-B). The biopsy confirmed a recurrent tumor, and the patient was given radiation treatment. Follow-up MRI examination demonstrated a decrease in the size of the mass.

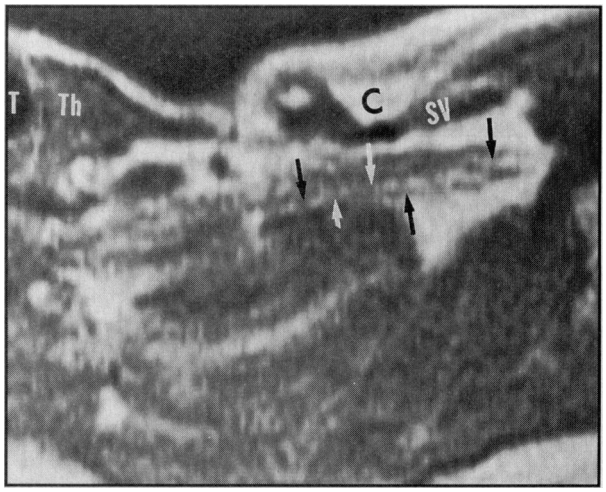

Figure 2. Enlarged oblique axial (transverse) image of the left brachial plexus. Notching and decreased signal of the brachial plexus cords is present (arrows) consistent with ischemic changes. (T = trachea, C = clavicle, SV = subclavian vein, and Th = thyroid.)

Neuropathy

Nerves are smooth and sharply defined organized phospholipids. Nerves on MRI are displayed as intermediate signals marginated by low signals.[4] Nerves have a defined blood supply and contain lymphatics in the epineurium and the perineurium. The lymphatics are not present in the endoneurium.[15,16] In the ischemic state, the nerve may be irregular and notched.

In the neuropathy category, a 49-year-old man presented with progressive peripheral neuropathy (Figure 2). His symptoms were most severe in the upper extremities. He was presented at the morning radiology rounds for possible MRI examination of the brachial plexus. Coronal and oblique axial T_1-weighted images were obtained, revealing notching and decreased signals of the brachial plexus. A third-year medical student suggested an antibodies-to-nuclear antigens (ANA) study, which was positive. The neurosurgeon biopsied the musculocutaneous nerve to the deltoid muscle, and the pathology report confirmed diagnosis of autoimmune disease as the cause of the peripheral neuropathy. This case was so fascinating that it was presented at the weekly UCLA neurology and neurosurgical grand rounds. The MRI demonstrated the pathology prior to the biopsy and enabled the neurosurgeon to biopsy the musculocutaneous nerve to the deltoid muscle, instead of the sural nerve in the lower extremity. The patient was placed on appropriate steroid treatment and showed improvement.

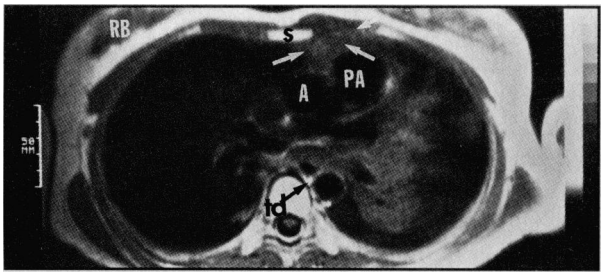

Figure 3. Axial (transverse) image demonstrating infiltration of Hodgkin's disease in the region of the left internal mammary lymphatics and chest wall (arrows). (TD = thoracic duct, S = sternum, RB = right breast, PA = pulmonary artery, and A = aorta.)

Lymphoma

Patients presenting with Hodgkin's disease are staged with lymphangiograms. Axillary nodes are not conventionally demonstrated with the plain radiograph. An upper extremity lymphangiogram may be necessary to image the axillary nodes.[17,18] Coronal chest MRI demonstrated enlarged nodes in two of the patients. Their radiation therapy ports were constructed to encompass the nodes. Six of the Hodgkin's patients had MRI examinations of the chest that demonstrated extension of tumors through the anterior chest wall. One of the six patients was a 32-year-old woman who presented with stage 2 Hodgkin's disease. The bipedal lymphangiogram demonstrated stage 4 disease. An MR of the chest and abdomen was performed postlymphangiogram. The MRI examination confirmed stage 4 disease and demonstrated Ethiodol oil in abnormal lymph nodes surrounding the superior mesenteric artery.[13]

Serial computed tomography (CT) and MRI examinations demonstrated no further progression of the disease. Months later, the patient developed clinical recurrence of disease requiring chemotherapy. A repeat MRI demonstrated progression of disease and the appearance of herpes zoster lesions on the skin with a small right pleural effusion. The lesions were located on the lower right chest wall and appeared as localized low-grade signals. The CT examination did not demonstrate skin lesions. The patient's condition deteriorated. The MR examination of the chest, abdomen, and pelvis was performed and demonstrated extension of the disease into the region of the internal mammary lymphatics (Figure 3). A CT examination demonstrated advancing disease of the mediastinum with suggestion of chest-wall invasion. An open biopsy was performed and confirmed the findings on the MR and CT examinations. The MR examination also revealed metastatic lesions to the liver and pelvis.

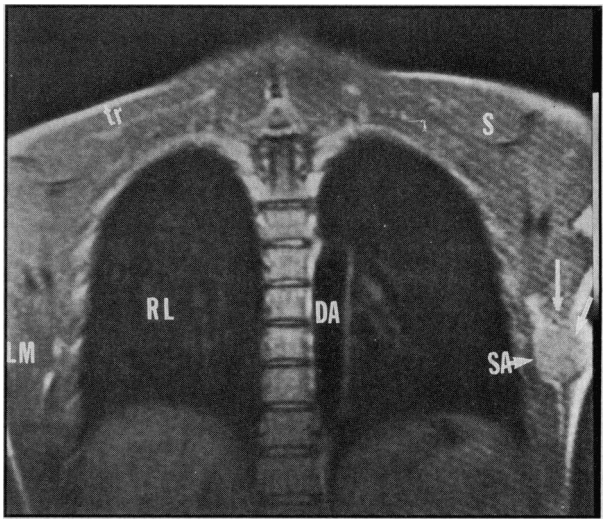

Figure 4. Coronal image of the chest demonstrating the intermediate signal of melanoma within three lymph nodes (arrows) displacing the latissimus dorsi (LM) and serratus anterior (SA) muscles. (DA = descending aorta, S = supraspinatus muscle, RL = right lung, and Tr = trapezius muscle.)

Melanomas

Patients with melanomas were imaged to demonstrate the smallest lesion that could be imaged on MRI. The patients were known to have various sizes of melanoma lesions in the skin. The smallest lesion measured 3 mm. Melanomas were displayed as intermediate signals in our study and often recurred at the same site after resection. The MRI examination was tailored to examine the contiguous anatomy and to display regional lymph nodes. The architecture of the enlarged node was not specific for melanoma. However, the demonstration of the enlarged nodes enabled the surgeon to plan resection and treatment.

One of the patients was a 28-year-old woman who had resection for melanoma of the left lateral chest wall. Three months later, swelling occurred at the site of resection. A CT scan was not requested because the physician wanted to see the contiguous anatomy displayed. The MR of the chest was tailored to the lesions on the left lateral chest wall, demonstrating three distinct intermediate signals (Figure 4). No additional masses were detected. Surgery confirmed the findings on the MR. The metastatic lesions were removed and recurred several months later. A repeat MRI detected widespread disease.

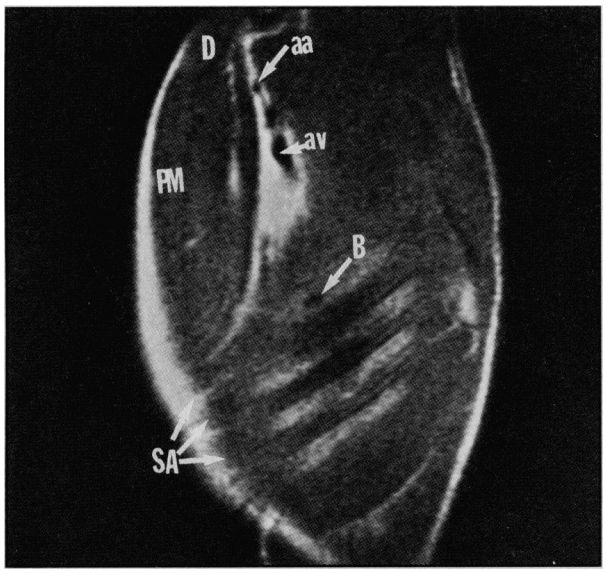

Figure 5. Oblique sagittal image of the normal chest wall except for the low signal of the biopsy (B) site. (SA = serratus anterior muscles, aa = axillary artery, av = axillary vein, PM = pectoralis major muscle, and D = deltoid muscle.)

In past years, a lymphangiogram would have been performed to detect metastasis if the lesion involved the lower or upper extremities.[19] The metastatic lesion may have been detected as a lucent defect within the inguinal or periaortic nodes on the lymphangiogram. In this case, a routine lymphangiogram would not have been practical, and CT may have imaged the lesion. However, CT would not have imaged the contiguous anatomy to give the surgeon the information necessary for resection.

Normal

Magnetic resonance imaging of the chest demonstrates sharp, well-defined muscles and fascial plane anatomy.[4] The serratus anterior muscles are well-defined as finger-like structures on the oblique sagittal sequence of the male and female chests.

In the normal anatomy category, a 22-year-old male swimmer presented with a "bump" on the left chest wall. The biopsy performed prior to the MR examination was negative. The surgeon requested an MR examination to rule out tumor. The MRI demonstrated relatively enlarged normal serratus anterior muscles. The biopsy site was identified as a low signal within the serratus muscle. No tumor was demonstrated (Figure 5). No further workup was necessary.

Lung Carcinoma

In the lung carcinoma category, four patients with known diagnoses were studied; each presented with localized swelling over the ribs. Bone scans were suggested and demonstrated a positive uptake of the isotope within the rib margins. Two of the patients had possible rib lesions on the chest radiograph. The MR examination confirmed rib involvement without soft tissue extension. The diagnosis of carcinoma was not suspected in the third patient, who complained of chest pain. A radiograph revealed a left pleural effusion. Thoracentesis under fluoroscopic control was performed.[9] The pleural fluid was positive for adenocarcinoma. Rib destruction was detected during the thoracentesis examination. A fluoroscopic spot film confirmed destruction of the left 5th anterior rib. Chest MR confirmed tumor involvement of the left lung with extension to the ribs and the pericardium (Figures 6A-B).

A percutaneous rib biopsy was performed under fluoroscopic control.[5] The pathology confirmed the diagnosis of adenocarcinoma. The patient received combined radiation therapy and chest wall surgery. Repeated MR chest examinations were performed at 3-month intervals. One year later, a mass lesion was detected in the left lung field. Chemotherapy was repeated; the lesion disappeared. Thereafter, every 3 months an MR examination of the chest was performed showing a stable chest. The patient is alive and free of tumor after 4 years.

The fourth patient had a known diagnosis of oat cell carcinoma of the right lung. A rib lesion was detected on the plain chest radiograph. The MR examination revealed tumor extension to one rib. A percutaneous biopsy was performed under fluoroscopic control for tissue diagnosis and receptor cell studies. The biopsy confirmed the diagnosis. No receptor cells were present. Local radiation was given.

Keloids

Three patients were studied as dermatologists wanted to see if there were any characteristic MRI signals. The lesions were imaged for baseline studies and anatomical pathological correlation. The MR study demonstrated a central intermediate signal extending from the base of the keloid to the surface of the lesion. The central portion of the keloid had the appearance of a "volcano" on the oblique sagittal image (Figure 7).

Lymphedema

Ten patients were imaged; all had swelling of the

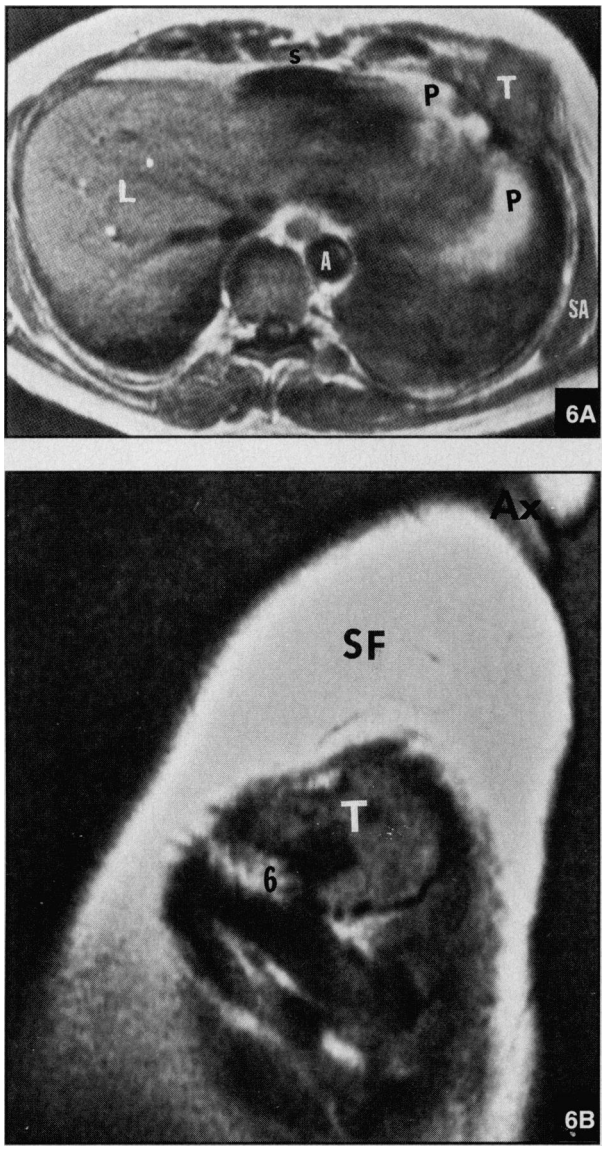

Figures 6A-B. Axial (transverse) and oblique sagittal image demonstrating the intermediate signal of the infiltrating adenocarcinoma of the ribs and soft tissues. (T = tumor, P = pericardial fat, S = sternum, L = liver, A = aorta, SA = serratus anterior muscle, Ax = axilla, SF = subcutaneous fat, and 6 = sixth rib destruction.)

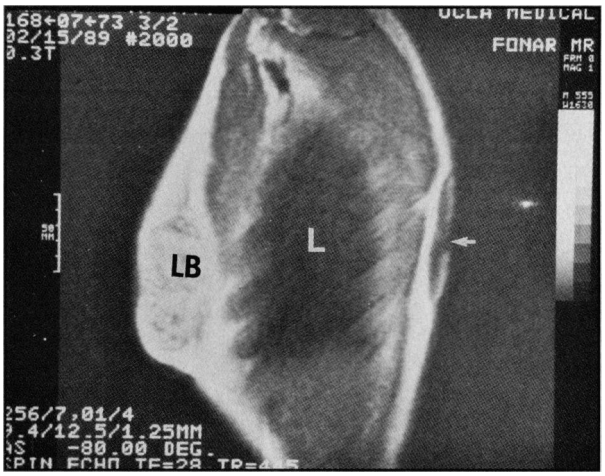

Figure 7. Sagittal view of a female chest demonstrating the "volcano" sign (arrow) of a large keloid extending from the posterior to the anterolateral chest. The low signal is the nidus of the keloid that extends from the surface to the base of the lesion. (LB = left breast, L = lung, and PM = pectoralis major muscle.)

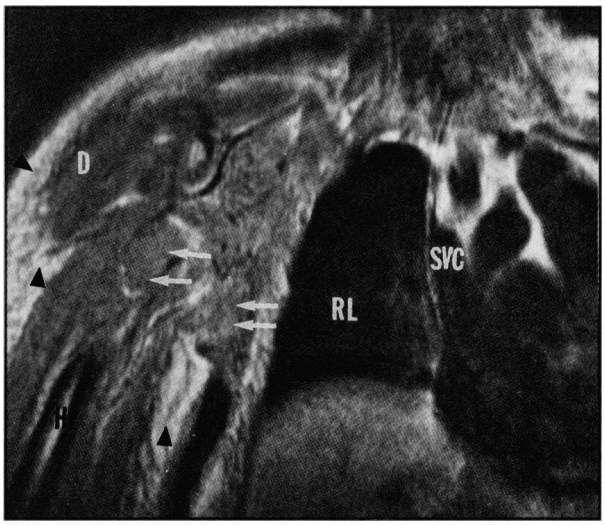

Figure 8. A coronal view of the chest demonstrates infiltrating carcinoma with unilateral edema and tumor masses (white arrows). Note the intermediate signal of the edematous skin and the low signals of the dilated lymphatics and veins (arrow heads). (D = deltoid muscle, H = humerus, RL = right lung, and SVC = superior vena cava.)

chest wall. Six had histories of breast carcinoma with question of metastatic disease to the axillary nodes. Three of the six had tumor infiltration of the ribs and soft tissues as determined by MRI. They received radiation therapy. The remaining three patients were negative for nodal enlargement and tissue infiltration. The seventh patient had known metastatic tumor infiltrating the chest wall and shoulder girdle. A sinogram was requested to rule out a draining sinus tract. No sinus tract was demonstrated. The MR demonstrated infiltrating tumor of the chest wall with

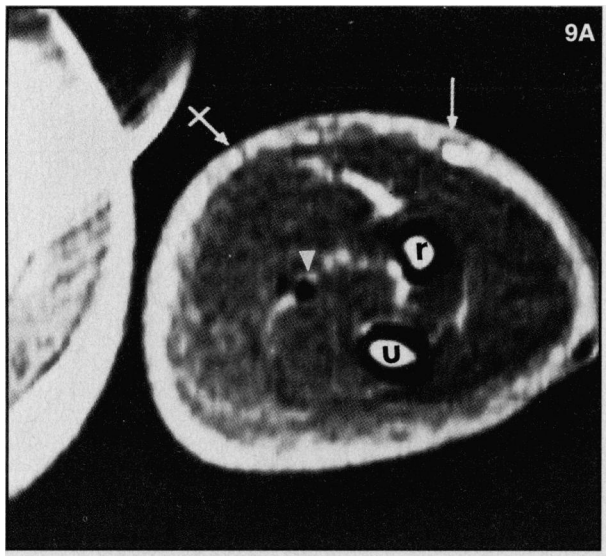

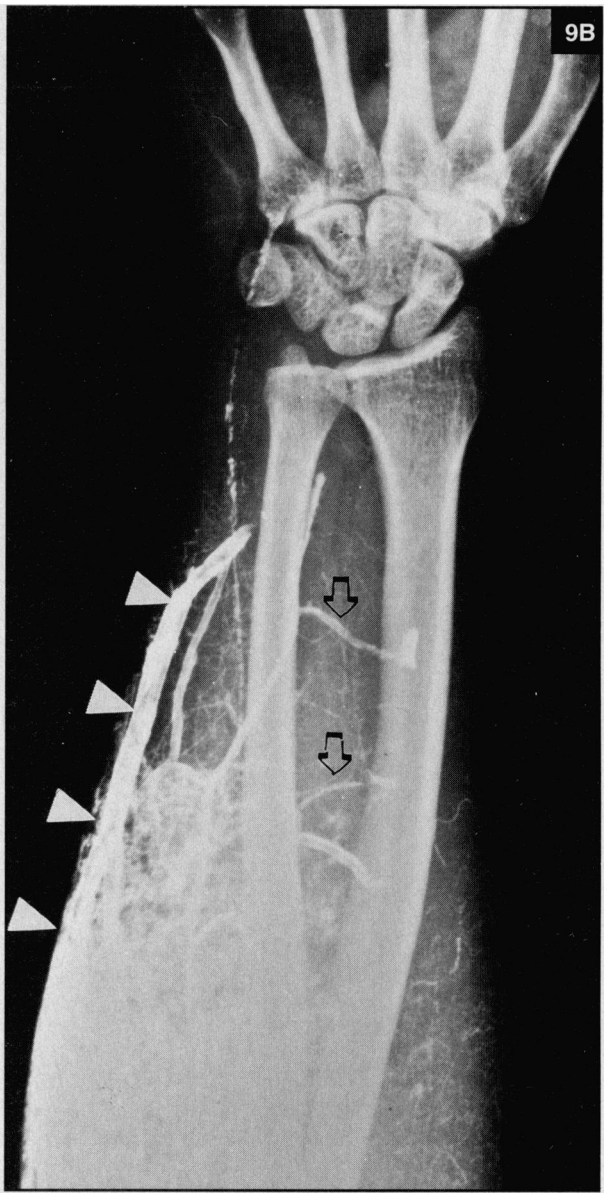

Figures 9A-B. AP radiograph and an axial MR view of the lower arm demonstrating obstructive lymphedema post lymphangiography. Edema of the chest wall, shoulder girdle, and left upper extremity is the result of the thoracic duct tumor. Note the dilated lymphatics in the skin (arrow with bar) and the dilated cephalic vein (plain arrow). The collaterals are indicated by the arrows) and perivascular stasis by the arrow heads. (u=ulna and r=radius.)

asymmetrical enlargement of the overlying tissues (Figure 8).

The eighth patient, a 29-year-old man, presented with swelling of the left arm and shoulder girdle. Vascular workup included a venogram, which was negative. An upper extremity lymphangiogram demonstrated lymphatic obstruction, nonvisualization of the thoracic duct, swelling of the upper extremity, collateral lymphatics, perivascular lymphatic stasis, and lymphatic dermal backflow (Figure 9A).[3] The MR examination was performed after the lymphangiogram. Ethiodol oil was demonstrated as perivascular high signals surrounding vascular structures in the arm, and oil was displayed within dilated collateral lymphatics in the skin and subcutaneous tissues (Figure 9B). The thoracic duct was notched and dilated. Open biopsy of the thoracic duct as it entered the left subclavian vein revealed adenocarcinoma obstruction of the thoracic duct. Therefore, in some instances shoulder edema may be attributed to obstruction of the thoracic duct.

The ninth patient was a 76-year-old woman who developed painful swelling of the right arm 20 years postremoval of the right breast. Chest radiograph was negative. A CT demonstrated a nodule in the apex of the right lung. The biopsy at the outside institution was negative. The MR examination revealed an organized clot in the right brachiocephalic vein. The patient was followed with serial MR examinations at 3-month intervals for 3 years. The clot remained stable, and the patient remained free of tumor.[14] In this case, partial venous obstruction coupled with the radical mastectomy contributed to her painful swelling.

The tenth patient had swelling of the anterior right chest wall. The oncologist requested an MR examination to rule out tumor. The MR examination revealed erosion of the manubrium sternum by a mass with

nonspecific swelling of the right chest wall. The percutaneous biopsy confirmed tumor.

Sarcomas

Three patients were studied. Two had confirmed diagnoses of sarcoma, and the third had a granulomatous process involving the right chest wall. He was a 47-year-old man complaining of painful swelling of the right chest wall. A suspected diagnosis of sarcoma of the chest wall was made by his clinician, who referred the patient to the UCLA Bowyer Oncology Clinic. An MR examination of the chest was performed prebiopsy demonstrating asymmetrical enlargement of the right chest wall and erosion of the manubrium sternum compatible with an inflammatory process because there was no low-grade signal (tumor) within the surface anatomy (Figure 10). Laboratory results confirmed an inflammatory agent.

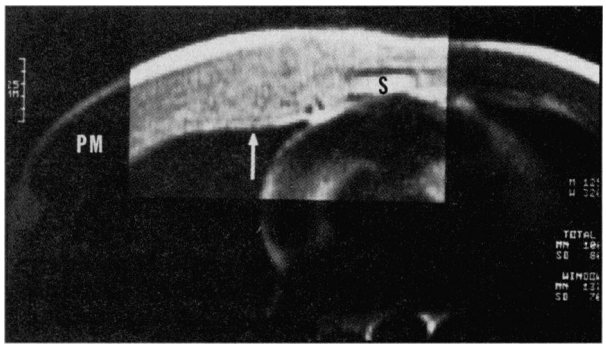

Figure 10. Axial (transverse) image of the anterior chest wall demonstrating inflammatory erosion of the manubrium sternum (S) with asymmetrical thickening of the right chest wall (arrow). (PM = pectoralis major muscle.)

DISCUSSION

The above cases demonstrate several lesions of the chest wall that were not clearly detected by plain chest radiographs or CT. The MRIs provided multiplane imaging, which allowed the radiologist to comment about the contiguous anatomy and to determine the extent of disease. Because swelling was a common factor in chest wall lesions, it can be concluded that the lymphatic system plays an important role in the spread of disease involving the chest wall. The lymphatic system is a closed system and parallels the development of the venous system.[20] When a tumor obstructs lymph vessels, a collateral circulation reroutes the lymph drainage. Lymphedema may result with swelling and dermal backflow.[6] Breast carcinomas, congenital absence of lymph nodes and channels, lymphomas, melanomas, sarcomas, surgical resections, and infections have all produced lymphedema in patients documented by upper and lower extremity lymphangiograms at UCLA.

We have constructed two models to demonstrate the results of lymphatic obstruction. A canine model was constructed to demonstrate the effects of lymphatic obstruction in one extremity,[3] and a pig lung model was constructed for lymphatic anatomy and cannulation for transplantation, and to demonstrate the effects of lymphatic obstruction in the lung.[21]

The endstage Hodgkin's disease patients indicated that the spread to the chest wall may be caused by the blockage of the internal mammary lymphatic chain. The recurrence of mediastinal disease obstructing the normal mediastinal flow shunts the lymph with tumor cells into the adjacent collateral circulation. The circumvention of Ethiodol oil is common in patients presenting with tumor blockage in the pelvis and abdomen. Retrograde injection of Ethiodol oil into peribronchial lymphatics of the pig lung demonstrates collateral channels communicating with both lungs.[20,21] The surface lymphatics of the trachea, proximal bronchi, and pleura become dilated with introduction of the ethiodol, demonstrating the closed continuous communication of the lymph system. Surgical resection of the lung and soft tissues interrupts the normal lymph flow and may allow abnormal cells to remain in the blind ends of the lymph channels. Therefore, tumors and infections may spread locally or by circumvention to other sites despite the small valves in lymphatic channels of the thorax and lungs.[3,22]

The MR examination of the chest wall demonstrates lesions not imaged by conventional chest radiographs and CT. Faster imaging with MR and higher resolution will demonstrate greater anatomical detail. Therefore, patient management may be improved by the anatomical detail that magnetic resonance has provided. The advantage of obtaining an MR prior to invasive procedures may allow improvement of patient care for the clinician and radiologist in planning appropriate therapy.

CONCLUSION

The following recommendations are offered:

- an MRI should be used in chest wall imaging because it can demonstrate fascial plane separation and continguous anatomy,
- enlarged selected MR images are needed to demonstrate the pathology, and

- the radiologist should orchestrate the MR examinations for better patient care.

The above recommendations are suggested because teaching depends on accurate interpretation of radiological examinations for pathological correlation of disease. The accurate imaging of disease has become the radiologist's forte. Magnetic resonance imaging demonstrates vivid anatomical detail that cannot be duplicated by any other modality (ie, CT or ultrasound).[4,10] However, MR can be coupled to other imaging modalities to enhance pathological descriptions. Magnetic resonance imaging allows multiplane imaging without surgical dissection, giving the patient an alternative to surgery and invasive procedures that may endanger his health.

Literature Cited

1. Collins JD, Furmanski S, Burwell E, Steckle R. Minimal detectable pleural effusions: a roentgen pathological model. *Radiology.* 1972;105:49-51.

2. Collins JD, Furmanski S, Burwell D, Steckle R. Minimal detectable calcification demonstrable in pulmonary nodules: a roentgen pathological model. *Radiology.* 1972;105:51-53.

3. Collins JD, Bassett LW, Snow H, Ross NA, Patin T. False positive thromboscintigram resulting from lymphedema: a roentgen pathological model. *J Natl Med Assoc.* 1986;78:875-881.

4. Collins JD, Shaver M, Batra P, Brown K. Nerves on magnetic resonance imaging. *J Natl Med Assoc.* 1989;81:2:129-134.

5. Collins JD, Bassett L, Main G, Kagan C. Percutaneous biopsy following positive bone scans. *Radiology.* 1979;132:439-442.

6. Henze E, Shelbert HR, Collins JD, Najafi A, Barrio JR, Bennet LR. Tc 99m labeled dextran a new radiopharmaceutical for radionuclide for lymphangiography. *J Nucl Med.* 1982;3:923-929.

7. Steckle RJ, Snow HD, Collins JD, Barenfus L, Patin T. Successful radiation protection of the normal intestinal tract in the dog. *Radiology.* 1974;111:51-455.

8. Steckle RJ, Collins JD, Snow HD, et al. Radiation protection of the normal kidney by selective arterial infusions. *Cancer.* 1973;34:1046-1058.

9. Collins JD, Byrd S, Bassett L. Thoracentesis under fluoroscopic control by a radiologist. *JAMA.* 1977;237:2751-2752

10. Collins JD, Batra P, Brown K, Shaver M. Anatomy of the thorax and shoulder girdle as displayed by magnetic resonance imaging. *Anat Rec.* 1986;214:24A.

11. Collins JD, Shaver M, Batra P, Brown K. Anatomy of the abdomen, back, and pelvis as displayed by magnetic resonance imaging, part 1. *J Natl Med Assoc.* 1989;81:680-684.

12. Collins JD, Shaver M, Batra P, Brown K. Anatomy of the abdomen, back, and pelvis as displayed by magnetic resonance imaging, part 2. *J Natl Med Assoc.* 1989;81:809-812.

13. Collins JD, Shaver M, Batra P, Brown K. Anatomy of the abdomen, back, and pelvis as displayed by magnetic resonance imaging, part 3. *J Natl Med Assoc.* 1989;81:857-861.

14. Clemente C. *Anatomy: A Regional Atlas of the Human Body.* 3rd ed. Baltimore, Md: Urban & Schwartzenbery; 1987.

15. Sunderland S. Blood supply of the nerves to the upper limb in man. *Archives of Neurology and Psychiatry.* 1945;53:91-115.

16. Dyck PJ, Varnes J, Lais L. *Pathologic Alterations of the Peripheral Nervous System of Humans: Peripheral Neuropathy.* 2nd ed. Philadelphia, Pa: WB Saunders Co; 1986:861.

17. Weisenberg TH, Juillard G. Axillary lymphangiograms in radiation therapy of lymphomas. *Radiology.* 1974;113:463-465.

18. Weisenberger TH, Julliard G. Upper extremity lymphangiogram in the radiation therapy of lymphomas and carcinoma of the breast. *Radiology.* 1977;122:227-230.

19. Collins JD. Bipedal lymphangiography (technique and diagnosis). Presented at the Midwinter Conference of the Los Angeles County Radiological Society; January 31, 1975; Los Angeles, Calif.

20. Moore KL. *The Developing Human.* 2nd ed. Baltimore Md: WB Saunders Co; 1977:284.

21. Collins JD, Batra P, Brown K, Shaver M. Anatomy of the lymphatic drainage as displayed by plain x-ray and as displayed by magnetic resonance imaging. *Anat Rec.* 1990;226:21A.

22. Armstrong P, Wilson AG, Dee P. *Imaging of Diseases of the Chest.* Chicago, Ill: Year Book Medical Publishers Inc; 1990.