

A Woman With Complications From Radiation Therapy

James D. Collins, MD

Keywords: radiology ■ anatomy ■ CT ■ PET scan ■ radiation therapy ■ skin ulceration

J Natl Med Assoc. 2010;102:1247-1250

Author Affiliations: University of California at Los Angeles, Department of Radiological Sciences, Los Angeles, California.

Correspondence: James D. Collins, MD, University of California at Los Angeles, Department of Radiological Sciences, 10833 Le Conte Ave, BL-428 CHS/UCLA mail code 172115, Los Angeles, CA 90095 (jamesc@mednet.ucla.edu).

CLINICAL HISTORY

This case is about a 77-year-old right-hand-dominant female beautician with a 50-year pack history of smoking cigarettes. She presented to the emergency department with generalized weakness, shortness of breath, and hemoptysis of 3 days' duration. Her private physician ordered posterior-anterior and lateral chest x-rays. The outside radiologist compared the chest x-rays to earlier radiographs. The posterior-anterior chest x-ray revealed a left paravertebral soft-tissue density superior to the aorta, irregular interstitial process at the left lung base, and a left pleural effusion. The lateral chest x-ray confirmed bilateral hyperinflated lungs but did not clearly identify the left lung mass. Laboratory studies were obtained 2 weeks prior to her scheduled hospital admission for computed tomography (CT)-guided lung biopsy. An intravenous needle was introduced for vascular access. A 19-gauge needle was introduced in the prone position, obtaining 3 separate cores without complication. The postprocedure radiograph did not reveal a pneumothorax. The pathology report from the lung tissue sections demonstrated infiltrating adenocarcinoma, fibrosis, and chronic inflammation. Normal lung tissue was not identified in the selected section. She was then scheduled for 6 weeks of combined outpatient radiation therapy and chemotherapy. She was readmitted to the hospital for an unusual hypersensitivity to radiotherapy, including severe esophagitis (treated with oral viscous xylocaine) and radiation burn/skin erythema. She successfully responded to treatment and was discharged to follow-up. Six months later, she had a positron emission tomographic (PET) CT scan.

PHYSICAL EXAMINATION

On admission, her blood pressure measurement was 150.80 mm Hg in the left arm: pulse, 72 beats/min with normal rhythm; height, 1.55 m; weight, 58 kg with a 3.6-kg weight loss in 6 weeks.

LABORATORY RESULTS

- Protein, total and protein electrophoresis: high and out of range, verified by repeat analysis
- Comprehensive metabolic panel: low sodium, carbon dioxide, albumin, and albumin/globulin: high protein, total; globulin
- Partial thromboplastin time, activated within normal limits
- Prothombin time: high
- Complete blood count: low white cell count, hemoglobin, and absolute neutrophils

RADIOGRAPHIC, CT, PET, AND PHOTOGRAPHIC FINDINGS

A portable anterior-posterior chest radiograph post left lung biopsy (Figure 1) displays a left hilar mass, vascular shift to the right lung, bilateral interstitial fibrosis, right greater than left, and bilateral hyperinflation consistent with chronic lung disease. The CT chest without contrast (Figures 2 and 3) displays the left hilar mass encompassing the left hilum, particularly the left upper lung bronchus. The PET scan (Figure 4) displays positive right anterior-posterior hilar window mass, left upper lobe paratracheal mass, right and left hilar, subcarinal adenopathy, and right lower lobe soft-tissue mass. A color photograph (Figure 5) displays the chemotherapy skin ulcer over the patient's back marginating the posterior-anterior field/port post radiation. Since it is not possible to display all images that were made available, those selected best displayed the pathology.

The following studies were reported by the outside radiologist to the patient's daughter, but were not available for review. Brain CT with contrast showed no evidence of metastatic disease or significant change from 1 year ago. Diffuse cortical atrophy showed no evidence of focal mass, hemorrhage, or midline shift. Stable old ischemic changes with encephalomalacia were found in the right posterior parietal-occipital region. Chest x-ray

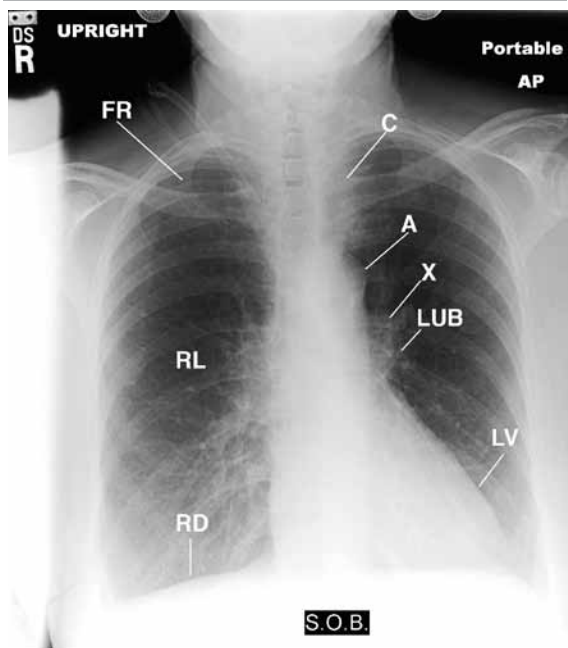
6 months post lung biopsy displayed hyperinflation consistent with underlying chronic obstructive pulmonary disease. Diagnostic esophagogastroduodenoscopy (scope of the esophagus, stomach, and duodenum), 6 months post lung biopsy showed a normal esophagus without mucosal abnormality and a hiatal hernia.

RADIATION TREATMENT SUMMARY

Diagnosis

The diagnosis was adenocarcinoma of the lung, T3, N3, Mo, stage III-B. The treatment period is 6 weeks for adenocarcinoma of the left lung.

Figure 1. Portable anterior-posterior chest radiograph displaying intravenous tubing over the right neck (not labeled); drooping right shoulder as compared to elevated left shoulder, anterior-rotated heads of the clavicles (C) over the posterior asymmetric 6th intercostal spaces (not labeled); hyperlucent left lung secondary to decrease vascular flow/left upper lobe tumor (X) compromising the left upper lobe bronchus (LUB) and pulmonary artery; asymmetric hyperinflated lungs flattening the diaphragm, right (RD) greater than left (LD); shallow left costophrenic sulcus (CS), reflecting a small pleura effusion vs scarring and fibrosis; retracted right cardiophrenic sulcus (not labeled) as compared to the left; increased interstitial changes over the right lung (RL) base with straightening of the left pericardium reflecting old inflammatory disease.



A, aorta; FR, right first rib; LV, left ventricle; SOB, shortness of breath.

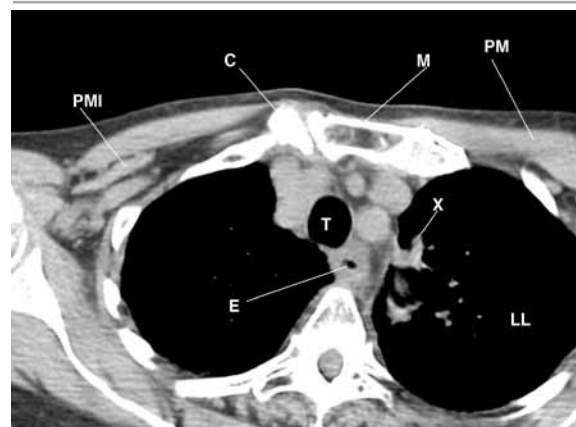
Dose/Technique

Initially, 3-D treatment was delivered using anterior-posterior/posterior-anterior fields to the left upper lobe mass, bilateral hila, and mediastinum: 200 cGy (a unit of absorbed dose of radiation) 1 cGy = 1 rad) was delivered with 15° of wedges and anterior-posterior field. A total of 4000 cGy were delivered over a period of 6 weeks. The treatment period was protracted as the patient took a long break, wanting to have chemotherapy sequentially rather than concomitantly with radiotherapy. The treatment was halted at 2000 cGy. She underwent a 5-day course of intravenous cisplatin and etoposide in the last month of the year, and she returned after the break to receive a total cumulative dose of 4000 cGy. To avoid normal tissue tolerance, especially to the spinal cord and esophagus, intensity-modulated radiation therapy (IMRT) was planned and treatment given as above. A total of 4 treatments of 800 cGy out of a planned dose of 2600 cGy by IMRT were administered. She developed difficulty in swallowing food, and treatment was terminated. She was admitted to the hospital for treatment complicated by unusual hypersensitivity to radiotherapy, including severe esophagitis and erythema/hyperpigmentation on the skin exposed to the radiation. Radiotherapy was discontinued on account of the patient's difficulty tolerating radiotherapy.

DISCUSSION

CT scan and magnetic resonance imaging (MRI) are special radiographic modalities used to image the thorax, shoulder girdle, brain, and soft tissues. Vascular structures, surface anatomy, and the soft tissues are

Figure 2. CT through the fascial plane of the tumor (X) marginating the left upper lobe bronchus; manubrium (M) sloping posterior left placing the head of the right clavicle (C) anterior inferior to the left. Observe the landmark anatomy for orientation to the surrounding structures.



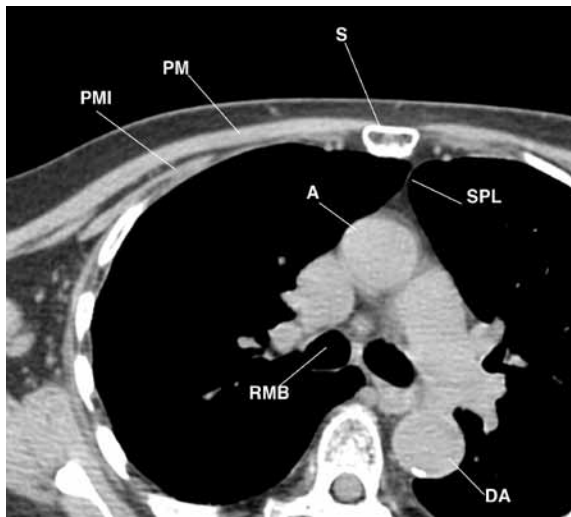
E, esophagus; LL, left lung; M, muscles; PM, pectoralis major; PMI, pectoralis minor; T, trachea.

incompletely imaged by conventional x-ray techniques. CT extends the capabilities of x-ray imaging to obtain detailed transverse (axial) anatomic sections, but CT does not definitively distinguish tumors from vascular or neurovascular structures, or both. CT does not allow satisfactory images of the soft tissues. CT 3-dimensional imaging of soft-tissue anatomy would have provided better display of the landmark anatomy in our patient. Multiplanar MRI would have perhaps been a better choice but was not made available.¹

Radiation therapy (radiotherapy) was selected to deliver high-energy rays to damage cancer cells. Some of the expected side effects include: loss of hair that may grow back at a different texture, anemia, severe esophagitis, and erythema/hyperpigmentation of the skin.² In our patient, ulceration of the skin occurred on the posterior port side and not on the anterior port side. The patient also underwent chemotherapy with cisplatin and etoposide, the side effects of which may include numbness, but not ulceration, of the skin. The reader may postulate that the combination of free-radical formation with the chemotherapy may have been a potential cause. However, review of the literature does not support this.

The ulceration over the patient's back is hard to explain. Perhaps hypersensitive may be the answer. Follow-up information indicates the patient was hospitalized with brain metastasis and was admitted to a hospice. Her gait became unsteady, and she is constantly nauseated.

Figure 3. This is a CT through the carina displaying tumor (X) left lateral to the arch of the ascending aorta (A), superior sternopericardial ligament off the left of midline (SPL), body of the sternum (S) sloping posterior left. Observe the thin subcutaneous tissues over the anterior chest wall (not labeled).



A, descending aorta; E, esophagus; PM, pectoralis major; PMI, pectoralis minor.

Figure 4. PET scan displaying left upper lung mass (X), left hilar lymph nodes, bladder (BL). Observe the ectopic extrarenal pelvis (KID).

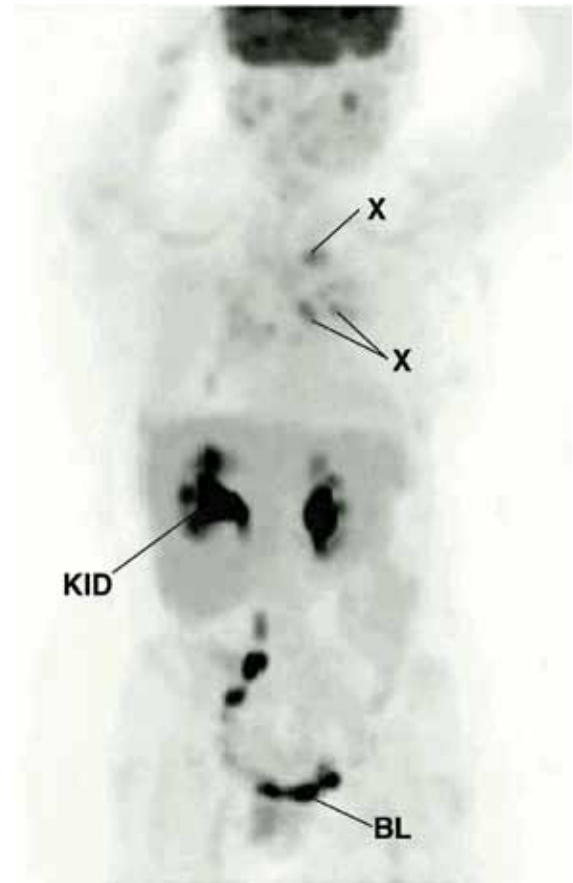
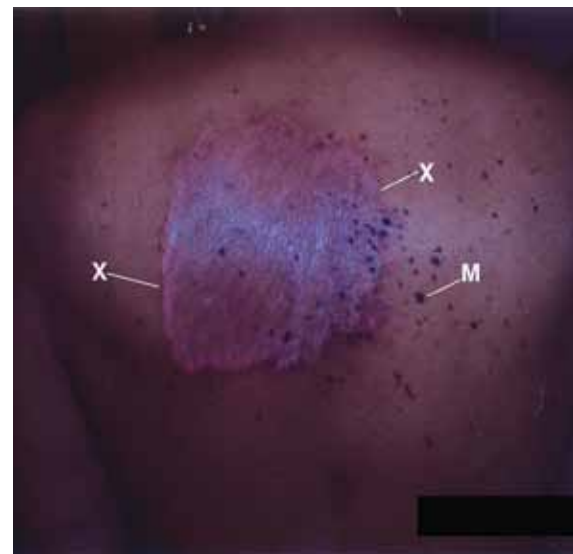


Figure 5. Patient's back, displaying the large ulceration/burn reaction. Observe the raised erythematous (X) margin of the skin reaction and pigmented moles (M).



TAKE-HOME MESSAGE

The lymph system is contiguous with the vascular system of the lung. The lymph system is a closed system, like the vascular system. Lungs are scarred from chronic infections, radiation therapy, and/or toxic agents.^{3,4} Our patient presented with hemoptysis for 3 days, indicating she had interrupted the vascular system and the lymphatics marginating the bronchi. The PET scan documented lymph metastasis. Delivered radiation presented opposing ports, but the tumor dose was not indicated. The patient developed ulceration over the posterior chest wall port but not over the anterior chest wall port. Had the tumor dose been indicated, a possible answer might have been the reason for the ulceration.

A patient and family members should be given full information of the proposed treatment and detailed

imaging studies—most of which was not provided to this patient. Copies of all the chest radiographs were not provided to her either. This information may be needed for future medical treatment.

REFERENCES

1. Collins JD, Shaver M, Disher A, Miller TQ. Bilateral Magnetic Resonance Imaging of the Brachial Plexus and Peripheral Nerve Imaging: Technique and Three-Dimensional Color. *Management of Peripheral Nerve Problems*, 2nd ed. Philadelphia, PA: WB Saunders Co; 1998:82-93.
2. Moss W. *Therapeutic Radiology*, 2nd ed. 1965:378-379.
3. Collins JD, Disher A, Shaver M, Miller TQ. Imaging the Hepatic Lymphatics: Experimental Studies in Swine. *J Natl Med Assoc*. 1993;3:185-191.
4. Collins JD, Shaver M, Disher A, Batra P, Brown K, Miller TQ. Imaging the Thoracic Lymphatics: Experimental Studies of Swine. *Clin Anat*. 1991;4:433-446. ■